

REVIEW ARTICLE

Correspondence:

Wayne J.G. Hellstrom
Tulane University Health Sciences Center,
Department of Urology, 1430 Tulane Ave. SL-42,
New Orleans, LA 70112, USA.
E-mail: whellst@tulane.edu

Keywords:

erectile dysfunction, Peyronie's disease, treatment

Received: 27-Mar-2015

Revised: 30-Apr-2015

Accepted: 5-May-2015

doi: 10.1111/andr.12058

Therapeutic advances in the treatment of Peyronie's disease

F. A. Yafi, M. R. Pinsky, P. Sangkum and W. J.G. Hellstrom

Department of Urology, Tulane University School of Medicine, New Orleans, LA, USA

SUMMARY

Peyronie's disease (PD) is an under-diagnosed condition with prevalence in the male population as high as 9%. It is a localized connective tissue disorder of the penis characterized by scarring of the tunica albuginea. Its pathophysiology, however, remains incompletely elucidated. For the management of the acute phase of PD, there are currently numerous available oral drugs, but the scientific evidence for their use is weak. In terms of intralesional injections, collagenase clostridium histolyticum is currently the only Food and Drug Administration-approved drug for the management of patients with PD and a palpable plaque with dorsal or dorso-lateral curvature $>30^\circ$. Other available intralesional injectable drugs include verapamil and interferon-alpha-2B, however, their use is considered off-label. Iontophoresis, shockwave therapy, and radiation therapy have also been described with unconvincing results, and as such, their use is currently not recommended. Traction therapy, as part of a multimodal approach, is an underused additional tool for the prevention of PD-associated loss of penile length, but its efficacy is dependent on patient compliance. Surgical therapy remains the gold standard for patients in the chronic phase of the disease. In patients with adequate erectile function, tunical plication and/or incision/partial excision and grafting can be offered, depending on degree of curvature and/or presence of destabilizing deformity. In patients with erectile dysfunction non-responsive to oral therapy, insertion of an inflatable penile prosthesis with or without straightening procedures should be offered.

INTRODUCTION

Peyronie's disease (PD) is a localized, connective tissue disorder of the penis characterized by scarring of the tunica albuginea. Fibrous plaque(s) deposited within the tunica albuginea impede the expansion of the tunica during erection, resulting in shortening, penile bending, indentation, and, often, pain. PD is regularly associated with the onset of erectile dysfunction (ED). What follows is a review of the current available knowledge regarding PD with a particular emphasis on recent therapeutic advances. Certain recommendations in this work reflect evidence-based findings, while others are based on expert opinion and will be highlighted accordingly throughout the manuscript.

Francois Gigot de la Peyronie, the personal physician to King Louis XV of France, first described this condition in 1743. PD has historically been perceived to be a rare, insignificant condition. The first description of the natural history of PD (Williams & Thomas, 1970) reported that the disease was one of 'gradual resolution,' with none of their 21 patients experiencing worsening

of his condition. This study led many clinicians to adopt a conservative approach to men with PD.

A questionnaire-based study in 1990 (Gelbard *et al.*, 1990) revealed that only 13% of patients with PD experienced symptom resolution, 40% of respondents reported progression, and 77% of patients experienced negative psychological consequences. Another study (Kadioglu *et al.*, 2000) supported the concept that PD was a progressive condition, reporting that spontaneous resolution was rare, while 30% of men not receiving any treatment experienced substantial deterioration. In this study, 63% of patients reported their disorder to be 'disabling.' Results from these studies contradict the general benign perception of PD, and implicated both physical and psychological consequences if left untreated.

PD has a prevalence of 3–9% (Rochelle & Levine, 2005) and most often occurs in older men (mean age 53, range 19–83 years). Disease onset is commonly associated with antecedent trauma, though the majority of men with PD do not have

any specific recollection of trauma. Of note, 10% of patients experience symptom onset before 40 years of age (Mulhall *et al.*, 2006). Aside from the physical deformities observed with PD, 20–54% of patients have associated ED (Usta *et al.*, 2004). Patients can exhibit any single presentation or a combination of penile plaque, curvature, penile pain, and ED. Plaques are typically located on the dorsal or lateral aspect of the penis, causing an upward or lateral deflection during erection.

Evaluation for PD needs to include a focused history and physical examination, a subjective erectile function questionnaire, and induction of an artificial erection to objectively measure penile curvature and document plaque characteristics; with penile duplex Doppler ultrasound (PDDU), if available. Alternatively, when PDDU is not readily available, a photograph of the patient's phallus in full erection may serve as an alternative tool for penile deformity assessment. A thorough history includes information about disease onset and duration, the presence of precipitating trauma, the degree of penile deformity, curvature, loss of penile length, ED, and the subjective level of sexual ability. It is also important to understand the degree of emotional and psychological impact that this disease has on a patient's interpersonal relationships. Standardized questionnaires, such as the International Index of Erectile Function (IIEF) and the Peyronie's Disease Questionnaire (Hellstrom *et al.*, 2013) are used for objective and subjective assessment and a means of measuring treatment efficacy over time.

Physical examination begins with a focused genitourinary evaluation and includes observation for the presence of Dupuytren's contracture or Lederhose scarring (plantar fibromatosis), both of which are associated with an increased incidence in PD. Objective measurements including stretched penile length, plaque location, and size are recorded. Vasoactive injections can obtain accurate baseline measurements to provide a standard against which progression or deterioration of the condition can be recorded at future visits. PDDU establishes penile vascular parameters, venous leakage, and erectile response, as well as plaque size, location, and presence of calcifications. Penile curvature is measured with any standard instrument, such as a protractor, or by photographs taken from multiple angles.

Treatment options are chosen based upon disease severity, patient preference, and surgeon training. Recognized options include oral meds, traction, intralesional injections, and various surgical approaches. Medical therapies are often employed in the early stages of PD, whereas surgical intervention is usually reserved for when PD has stabilized for at least six months. Management of patients with severe PD and significant penile curvature can be most challenging. Clinicians must always consider the natural history of PD during any management scheme. The decision for therapy is made on the basis of erectile status, presence of bothersome symptoms, motivation for treatment, realistic expectations, and overall psychological stability.

PATHOPHYSIOLOGY

Although the medical community has recognized PD for over 250 years, researchers have made little advancement toward understanding the etiology of PD, and providing effective prevention and treatment options. PD is hypothesized to begin with subclinical trauma to the penis. Most authorities suggest that PD is a disorder of wound healing, developing in genetically and/or

immunologically susceptible individuals (Bjekic *et al.*, 2006). Evidence for an underlying genetic predisposition can be found in its association with other fibrotic conditions such as Dupuytren's contracture. One study that compared the gene expression profiles of patients with PD and Dupuytren's noted similar alterations in the genes responsible for collagen deposition degradation, ossification, and myofibroblast differentiation (Qian *et al.*, 2004).

Transforming growth factor- β 1 (TGF- β 1) is recognized as one of the most fibrogenic cytokines, and is upregulated in PD plaques (Domes *et al.*, 2007). In rats, repeated injection into the tunica albuginea of adenovirus expressing TGF- β 1-induced fibrotic scarring in the tunica, and caused significant penile curvature, suggesting a possible role of TGF- β 1 in the pathogenesis of PD (Piao *et al.*, 2008). Genetic variations in the coding region of the TGF- β 1 gene have been documented in patients with PD, and the expression of the Smad transcription factors in the TGF- β 1 pathway were increased in fibroblasts of patients with PD (Haag *et al.*, 2007). The 1- β 1/Smad signaling pathway further delineates the intracellular mechanism by which TGF- β 1 mediates fibrosis. Therapies aimed at blocking the TGF- β 1 signaling pathway may be effective in the treatment or prevention of PD. More clinical research is obviously necessary to further delineate the pathophysiology of PD.

ORAL THERAPY

Currently, there are a number of oral agents available for the treatment of PD. These include vitamin E, potassium aminobenzoate (Potaba), tamoxifen, colchicine, carnitine, antioxidants, and phosphodiesterase (PDE) 5 inhibitors. Oral agents are attractive to PD patients because they are the least invasive option when compared to other modalities, such as intralesional injections and surgery. No oral agents, however, have documented significant, long-term efficacy. As such, the International Consultation on Sexual Medicine published guidelines that do not support the routine use of oral agents for the treatment of PD (Ralph *et al.*, 2010). Table 1 summarizes the available literature regarding various oral agents.

Vitamin E

Vitamin E (tocopherol) is a fat-soluble compound and was first used to treat PD in the 1940s (Scott & Scardino, 1948). Due to its low cost and wide availability, vitamin E remains the most commonly prescribed non-surgical option for treatment of PD (Levine & Burnett, 2013). Suggested mechanisms of actions are as a natural antioxidant, a free radical scavenger, and, potentially, an anti-inflammatory. Despite its longtime use, there is still insufficient data to support its use for the treatment of PD (Pryor & Farrell, 1983). Furthermore, two recent clinical studies demonstrated no clinical benefit to vitamin E monotherapy over non-medication or placebo (Hashimoto *et al.*, 2006; Safarinejad *et al.*, 2007). The combination of vitamin E with various other agents (verapamil, blueberries, propolis, and topical diclofenac) was also studied and demonstrated significant improvement in penile curvature ranging from -6.7° to -12.3° (Paulis *et al.*, 2013). This study, however, had a small number of patients and its results were not concordant with those from previously published studies on the combination of vitamin E with other agents (Inal *et al.*, 2006; Safarinejad *et al.*, 2007). Common adverse effects of vitamin E include nausea, vomiting, diarrhea,

Table 1 Studies of oral therapy for Peyronie's disease

Study	Design	N	Therapy	Duration	Outcomes
Safarinejad <i>et al.</i> , 2007	RCT-double blind, placebo controlled	236	300 mg Vit E twice daily, 1 g propionyl- L-carnitine twice daily, or combination compared with placebo	6 months	No statistically significant improvement in pain, curvature or plaque size in treatment arm
Paulis <i>et al.</i> , 2013	RCT-unblinded, not placebo controlled	70	Vitamin E (600 mg po daily) + verapamil (injection + iontophoresis) + blueberries + propolis + diclofenac gel or verapamil + blueberries + propolis + diclofenac gel without vitamin E	6 months	Significant improvement in plaque size reduction and penile curvature in vitamin E group
Weidner <i>et al.</i> , 2005	RCT-double blind, placebo controlled	103	3 g Potaba four times daily compared with placebo	12 months	Stabilizes plaques and prevents progression of penile curvature (no improvement of pre-existing curvature)
Teloken <i>et al.</i> , 1999	RCT-placebo controlled	25	20 mg tamoxifen twice daily compared with placebo	3 months	No statistically significant improvement in pain, curvature or plaque size in treatment arm
Safarinejad, 2004	RCT-double blind, placebo controlled	78	0.5–2.5 mg colchicine daily compared with placebo	4 months	No statistically significant improvement in pain, curvature or plaque size in treatment arm
Biagiotti & Cavallini, 2001	RCT-double blind, not placebo controlled	48	20 mg tamoxifen twice daily or 1 g acetyl- L-carnitine twice daily	3 months	Significant improvement in pain, penile curvature and disease progression in carnitine group
Safarinejad <i>et al.</i> , 2010	RCT-double blind, placebo controlled	228	400 mg pentoxifylline twice daily compared with placebo	6 months	Significant improvement in penile curvature and plaque volume
Ozturk <i>et al.</i> , 2014	RCT-unblinded, not placebo controlled	39	50 mg sildenafil daily or 400 IU vitamin E daily	3 months	Significant improvement in plaque volume and curvature in both groups but the difference between two groups were not statistically significant

RCT, randomized controlled trial.

headache, dizziness, possible cerebrovascular events, and some potential concern of increased prostate cancer risk (Klein *et al.*, 2011; Levine & Burnett, 2013; Desai *et al.*, 2014).

Potaba

Potaba has been used to treat PD since 1959 (Zarafonitis & Horrax, 1959). It has also been used for other fibrotic diseases such as scleroderma and Dupuytren's contracture (Zarafonitis, 1953). Its mechanism of action is thought to be through its anti-inflammatory and anti-fibrotic properties via a direct inhibitory effect on fibroblast glycosaminoglycan secretion and stabilization of serotonin-monoamine oxidase activity (Weidner *et al.*, 2005). To date, there is only one prospective randomized, double-blind placebo-controlled study evaluating Potaba's effect on PD, which showed significant improvement in penile plaque area after 12 months. There was, however, no significant change in pre-existing penile curvature. The authors concluded that Potaba might be useful to stabilize plaque and prevent progression of penile curvature (Weidner *et al.*, 2005). The adverse events of Potaba include skin photosensitization and gastrointestinal distress (Stoevesandt *et al.*, 2010; Gur *et al.*, 2011).

Tamoxifen

Tamoxifen is a non-steroidal estrogen receptor antagonist. It diminishes fibrogenesis in the tunica albuginea by modulating the release of TGF- β 1 from fibroblasts (Paulis & Brancato, 2012). In one uncontrolled study it demonstrated improvement in penile deformity in 11 of 31 patients (Ralph *et al.*, 1992). However, a subsequent randomized placebo control study did not reveal any significant improvement in pain, curvature, or plaque size in PD patients (Teloken *et al.*, 1999).

Colchicine

Colchicine theoretically diminishes wound contraction and inhibits collagen deposition by the downregulation of TGF- β 1 expression (El-Sakka *et al.*, 1999; Gur *et al.*, 2011). In a randomized double-blind, placebo-controlled study, however, colchicine did not demonstrate any benefit over placebo (Safarinejad, 2004). Furthermore, in a study of a combination of colchicine and vitamin E, researchers reported significant improvements in plaque size and penile curvature in the combination group compared to ibuprofen alone. This study, however, did not have a placebo arm and included only 45 patients (Prieto Castro *et al.*, 2003). A subsequent retrospective study reported no statistically significant differences in efficacy for pain relief, penile curvature, or plaque size between colchicine monotherapy and colchicine combined with vitamin E (Cortes-Gonzalez & Glina, 2010).

Carnitine

Carnitine is an acetyl coenzyme-A inhibitor that has anti-inflammatory properties (Gur *et al.*, 2011). Clinical trials of carnitine for the treatment of PD have shown conflicting results. In one study, carnitine taken twice daily for three months showed significant improvements in pain, curvature, and disease progression, when compared to tamoxifen (Biagiotti & Cavallini, 2001). Yet, a randomized double-blind placebo-controlled study evaluating carnitine monotherapy, or in combination with vitamin E, did not demonstrate any benefit in pain, curvature, or plaque size over placebo (Safarinejad *et al.*, 2007).

L-arginine

L-arginine is a nitric oxide precursor. Elevation of cyclic guanosine monophosphate (cGMP) by the activation of nitric oxide

synthase and nitric oxide is the possible anti-fibrotic mechanism of L-arginine (Valente *et al.*, 2003). In a rat model of induced glomerulonephritis, L-arginine supplementation significantly reduced TGF- β 1 expression and fibrosis in the kidney (Peters *et al.*, 2000). In a rat model of Peyronie's plaque, L-arginine demonstrated significant reduction in plaque size and decreased collagen type I expression (Valente *et al.*, 2003). As no human study of L-arginine for the treatment of PD has yet to be published, human clinical trials are needed to further confirm these findings.

Pentoxifylline

Pentoxifylline is a non-selective PDE inhibitor. In an in vitro study, pentoxifylline inhibited fibroblast proliferation and diminished collagen deposition and elastogenesis (Shindel *et al.*, 2010). It has also been shown to downregulate TGF- β 1 and increase fibrinolytic activity (Schandene *et al.*, 1992; Raetsch *et al.*, 2002). Furthermore, a double-blind, placebo-controlled study of 228 patients with early chronic PD demonstrated significant improvements in penile curvature and plaque volume with pentoxifylline (Safarinejad *et al.*, 2010). Reported adverse events include nausea, vomiting, dyspepsia, headache, and diarrhea. Blood pressure should be controlled during treatment due to the concern of associated peripheral vasodilation.

PDE-5 inhibitors

PDE-5 inhibitors increase cGMP levels by inhibiting the degradation of cGMP to GMP. Nitric oxide and cGMP provide anti-fibrotic activity by inhibiting collagen synthesis, myofibroblast differentiation, and reduction in oxidative stress (Gonzalez-Cadavid & Rajfer, 2010). In a rat model, sildenafil and pentoxifylline both stimulated fibroblast apoptosis in a PD-like plaque induced by TGF- β 1 and caused reduction in both plaque size and the collagen/fibroblast ratio (Valente *et al.*, 2003). Moreover, investigators reported a 69% resolution of isolated septal scars in patients after at least 6 months of using 2.5 mg tadalafil once daily (compared to 10% in the non-treatment group) (Chung *et al.*, 2011). None of the isolated septal scars, however, were clinically palpable and most patients in this study did not have any penile curvature. One may argue that the patients included in this study did not technically have 'real' PD. One recent study reported the treatment outcomes of patients with PD using 50 mg sildenafil daily or 400 IU vitamin E daily for 12 weeks.

Both groups demonstrated statistically significant improvements in penile curvature and plaque volume, but the differences between the two groups were not statistically significant (Ozturk *et al.*, 2014). Notably, the improvements in IIEF score and pain reduction were significantly better in the sildenafil group. This study, unfortunately, was not double-blinded and did not include a placebo group. As such, further large scale randomized double-blind placebo control studies are warranted to validate any clinical benefit of PDE-5 inhibitors for the treatment of PD.

INTRALESIONAL INJECTION THERAPY

The concept of a drug that could be injected directly into a PD plaque, causing either dissolution or at least a decrease in plaque size and, ultimately, improved penile curvature is certainly a very attractive therapeutic model. The impetus to discover and develop such therapy stems from the knowledge that oral therapy is not effective for PD, and surgical therapy is invasive and may be associated with serious side effects. Table 2 lists selected randomized prospective studies of intralesional injectable (ILI) drugs for PD.

Corticosteroids

The first reported use of an injectable agent for the management of PD dates back to 1952 with the intralesional administration of corticosteroids (Teasley, 1954). Owing to their anti-inflammatory properties, researchers postulated that corticosteroids could address the local inflammation within the tunica albuginea that leads to abnormal wound healing and, ultimately, fibrous plaque formation in PD. While an initial small retrospective study did show some improvement in penile pain and plaque size (Teasley, 1954), further studies failed to reproduce these results (Levine *et al.*, 2013). This has led most authorities to conclude that the observed effect of corticosteroids was likely a reflection of the natural progression of the disease. As such, ILI of corticosteroids currently is not recommended in the management of PD.

Calcium channel blockers

In 1994, Levine *et al.* introduced verapamil, a calcium channel blocker (CCB), as a potential intralesional treatment for PD (Levine *et al.*, 1994). This was based on the fact that CCBs can regulate fibroblast function and extracellular matrix production, while also exerting anti-inflammatory effects. While initial

Table 2 Intralesional therapy for Peyronie's disease

Intralesional drug	Mechanisms of action	Level of evidence	Common side effects	Conclusion
Corticosteroids	Anti-inflammatory effect, immune suppression	Case reports	Local tissue atrophy, thinning of the skin	No clinical benefit
Verapamil	Inhibition of calcium-dependent transport of extracellular matrix molecules; regulation of inflammatory response; inhibition of fibroblast proliferation	Randomized, placebo-controlled studies	Nausea, lightheadedness, penile pain, ecchymosis	Possible clinical benefit
Interferon alpha-2B	Regulation of immune responses; inhibition of fibroblast and collagen production, increased collagenase activity	Randomized, placebo-controlled studies	Myalgia, arthralgia, sinusitis, fevers, flu-like symptoms	Possible clinical benefit
Collagenase clostridium histolyticum	Degradation of interstitial collagens	Randomized, placebo-controlled studies	Injection-site pain, ecchymosis, corporal rupture	Clinical benefit (FDA approved)
Adipose tissue-derived stem cells	Prevention of fibrosis; immunomodulation; induction of phenotypical changes in resident fibroblasts	Animal studies	Not available	Benefit in animal model, no human studies

Adapted from Levine *et al.*, 2013.

reports showed significant improvements in curvature with ILI of verapamil (Levine *et al.*, 1994, 2002), later studies failed to display similar significant outcomes (Rehman *et al.*, 1998; Bennett *et al.*, 2007; Cavallini *et al.*, 2007; Shirazi *et al.*, 2009).

Furthermore, ILI of verapamil has been investigated as part of multimodal therapies for the management of PD. In one recent prospective randomized controlled trial, an additional benefit in terms of pain resolution and improvement in sexual function was observed when offered with an oral anti-oxidant, compared to ILI therapy alone (Favilla *et al.*, 2014).

Finally, ILI of nifedipine, another CCB, was recently examined in a prospective randomized trial and, while it did offer a benefit in terms of improvement in pain and erectile function, it did not significantly reduce penile curvature (Soh *et al.*, 2010).

Interferon-alpha

The potential role of interferon alpha-2B (IFN) as intralesional therapy for the management of PD dates back to *in vitro* studies conducted in 1991 (Duncan *et al.*, 1991). This led to the observation that ILI of IFN decreased the rate of fibroblast proliferation, decreased the production of extracellular collagen, and increased the production of collagenase in PD plaques (Hellstrom *et al.*, 2006).

Subsequently, a number of small pilot studies displayed clinical improvements in penile curvature, plaque size, and pain with ILI of IFN (Hellstrom *et al.*, 2006). The first randomized prospective controlled trial using ILI of IFN was reported in 2005 and showed similar significant improvements in penile curvature, plaque size, pain with erections, and penile hemodynamics (Kendirici *et al.*, 2005). The same group further confirmed these results in two larger trials (Hellstrom *et al.*, 2006; Trost *et al.*, 2013). Finally, a recent randomized prospective study examined the combination of ILI IFN with and without oral vitamin E but did not show any significant clinical effect with either treatment arm (Inal *et al.*, 2006).

Collagenase clostridium histolyticum

The most important recent development in the field of PD therapy came by way of two large randomized controlled trials, the Investigation for Maximal Peyronie's Efficacy and Safety Studies (IMPRESS) I and II which investigated the role of collagenase clostridium histolyticum (CCH) in the treatment of PD (Gelbard *et al.*, 2013a,b). Almost 30 years ago, Gelbard observed that CCH, a biological agent that enzymatically degrades interstitial collagens, was effective in the degradation of penile plaques and improvement of penile curvature in both *in vivo* and *in vitro* studies (Gelbard *et al.*, 1982, 1985).

The IMPRESS protocol consisted of 6-week cycles of two office-based intralesional injections followed by penile plaque modeling 24–72 h after the first cycle. Patients received up to four cycles (eight total injections) and were compared to a group receiving injections of saline. Patients with ventral curvature and extensive plaque calcification were excluded (Gelbard *et al.*, 2013a,b). Overall, at a 52-week follow-up, ILI CCH showed a mean 34% improvement in penile curvature (mean \pm SD -17.0 ± 14.8 degree change per subject), compared with a mean 18.2% improvement in placebo-treated men (-9.3 ± 13.6 degree change per subject) ($p < 0.0001$), and the mean change in PD symptom bother score was significantly improved in treated men vs. men on placebo (-2.8 ± 3.8 vs. -1.8 ± 3.5 , $p = 0.0037$).

Three serious adverse events (corporeal rupture) occurred in patients who were thought to have had strenuous sexual intercourse within 2 weeks of injection (Gelbard *et al.*, 2013a,b). Based on these positive results, in December 2013 the Food and Drug Administration approved CCH for the treatment of palpable plaque with dorsal or dorsolateral curvature $>30^\circ$.

Adipose tissue-derived stem cells

Regenerative medicine is a novel branch of medicine which, until recently, had not been applied to PD. Due the potential anti-fibrotic properties of mesenchymal stem cells (MSC), recent studies have sought to explore a potential role for adipose tissue-derived stem cells (ADSC), a type of MSC, in the management of PD, a fibrotic condition. To that aim, a PD-like rat model of fibrosis was developed by injecting transforming growth factor beta (TGF- β 1) into the tunica albuginea of a rat (Castiglione *et al.*, 2013; Lin & Lue, 2013; Gokce *et al.*, 2014). ADSCs were then injected 24 h later (acute phase) and seemed to both prevent the development of penile plaque formation, and improve erectile function (Castiglione *et al.*, 2013; Lin & Lue, 2013). It remains to be seen whether these results are reproducible in the chronic phase of PD and in humans.

IONTOPHORESIS

In an earlier effort to find non-invasive treatments for PD, researchers examined the role of a transdermally applied verapamil gel (Martin *et al.*, 2002). They noted a small amount of systemic absorption, but no penetration of the tunica albuginea. This prompted a search for a means to enhance the penetration of such topical (transdermal) medications. One such technique is iontophoresis, which is the use of an external electric force to electromotively induce the passage of ions through tissue. Data regarding the efficacy of iontophoresis with dexamethasone and verapamil with regards to curvature reduction have, however, been conflicting, and most urologists have since abandoned this modality (Riedl *et al.*, 2000; DiStasi *et al.*, 2004; Greenfield *et al.*, 2007).

SHOCKWAVE THERAPY

Because of the physical nature of PD plaques, investigators have explored a potential role for external shockwave lithotripsy (ESWL) as a treatment modality to reduce plaque burden and potentially improve penile curvature. While initially encouraging, data from a meta-analysis of 17 studies (Hauck *et al.*, 2004) and more recent prospective randomized controlled trials (Palmieri *et al.*, 2009; Hatzichristodoulou *et al.*, 2013) showed that while ESWL was effective with regards to penile pain and improved sexual function compared to natural history, it was not effective at reducing plaque size or degree of penile curvature. As such, ESWL is not currently recommended for the treatment of PD.

RADIATION THERAPY

Radiation therapy, like ESWL, has long been used for PD because of the precept that it could aid in plaque degeneration. However, recent mixed data have questioned its efficacy in plaque and penile curvature reduction and this has led to the overall recommendation against its use as a treatment modality for PD (Incrocci *et al.*, 2000; Mulhall *et al.*, 2012).

PENILE TRACTION THERAPY

Via mechanically induced signal transduction pathways and gene regulatory mechanisms, penile traction therapy (PTT) has been used for the remodeling of the extracellular matrix of PD plaques (Levine & Burnett, 2013). As a single modality, PTT has shown to be efficacious at reducing penile curvature and preventing PD-associated loss or gain of penile length in patients in both the acute (Martinez-Salamanca *et al.*, 2014) and chronic (Levine *et al.*, 2008; Gontero *et al.*, 2009) phases of PD.

When used concomitantly with ILI of verapamil, PTT has provided a significant duration-dependent (when used ≥ 3 h/day) increase in SPL compared to no PTT (Abern & Levine, 2008; Abern *et al.*, 2012). Similar results have been observed when PTT was used concomitantly with IFN with up to 4.4 mm gain in SPL when used for at least 3 h/day (Yafi *et al.*, 2014). There is currently no reported data regarding its use in combination with CCH.

Finally, loss of penile length following surgery for PD is a major complaint for most patients irrespective of surgical technique. The use of PTT has, however, been associated with a 1–3 cm gain in SPL when used as a pre-operative (Levine & Rybak, 2011) or post-operative (Moncada-Iribarren *et al.*, 2007) modality in conjunction with definitive surgical therapy for PD. Overall, PTT is an underused tool which, when used diligently, may provide a clinically significant benefit in penile length. It is worth noting, however, that the evidence regarding its usefulness is mostly based on small retrospective series, and as such, further larger prospective studies on this topic are warranted.

SURGICAL THERAPY

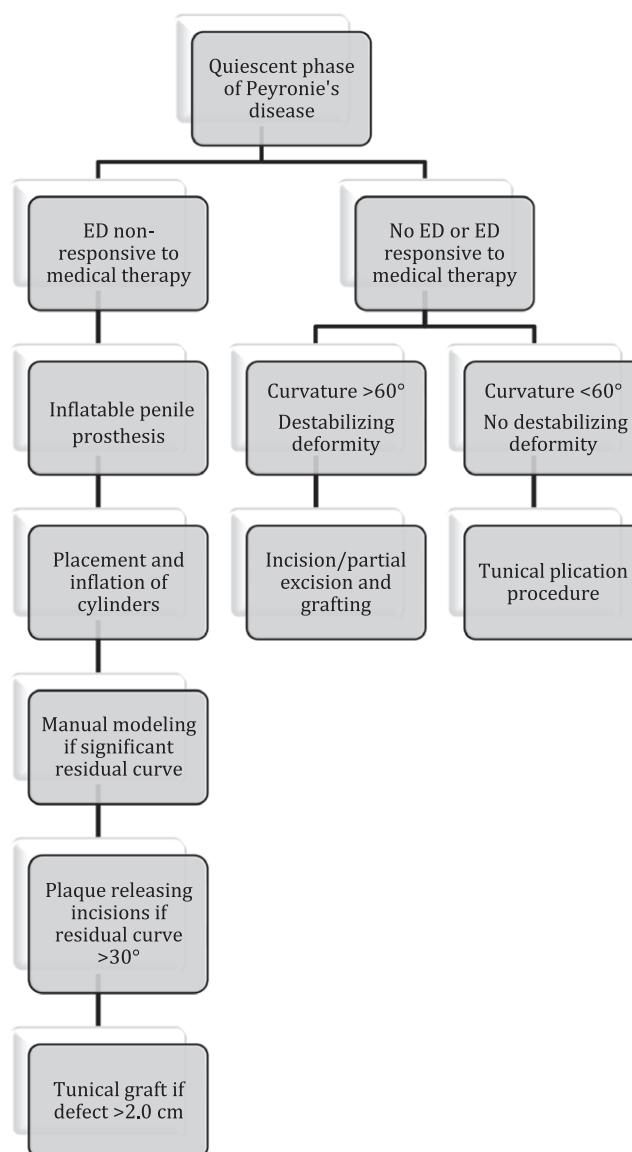
Surgical therapy is advocated only for men in the quiescent, or chronic phase of PD (at least 1 year from the time of onset and at least 6 months of no change in the penile deformity) who is unable to engage in satisfactory coitus, fails medical treatment, or when the patient requests the most rapid and reliable end-result (Ralph *et al.*, 2010; Hatzimouratidis *et al.*, 2012; Yafi *et al.*, 2015). Surgery aims to correct the penile curvature or deformity, preserve or restore erectile function, and prevent loss of penile length and girth. Prior to proceeding with any surgical intervention, it is crucial for the surgeon to have a frank discussion with the often-distressed patient regarding realistic expectations and potential complications of surgery. Accordingly, a consent should include the potential for: persistent/recurrent curvature, functionally straight $<20^\circ$ penis, loss of penile length, diminished rigidity, decreased sexual sensation, and ED.

Currently available surgical options include tunical plication procedures such as the Nesbitt and modified plications; tunical lengthening procedures (plaque incision or partial excision and grafting); and penile prosthesis (PP) implantation for men with concurrent ED. Figure 1 summarizes a widely used algorithm for the surgical management of PD.

Tunical plication procedures

Numerous tunical plication procedures including variations of a corporoplasty and a tunica albuginea plication (TAP) are available to the urologist. The first reported technique was the Nesbitt procedure, which entails excision of a piece of tunica albuginea on the contralateral side of the curvature (Nesbitt, 1954; Andrews *et al.*, 1999). Since then, the modified Nesbitt, Yachia, Essed-Schroeder, Duckett-Baskin-Levine, and 16-dot or 24-

Figure 1 Algorithm for the surgical management of Peyronie's disease.



dot plication techniques have been reported (Essed & Schroeder, 1985; Yachia, 1990; Baskin & Duckett, 1994; Gholami & Lue, 2002; Brant *et al.*, 2007).

These procedures work by shortening the long side of the penis and accordingly may result in an overall loss of penile length. In a review of 102 patients, the direction of curvature (ventral and ventrolateral) and the degree of curvature measured at the time of surgery (particularly when > 60 degrees) significantly predicted the amount of penile length loss (Greenfield *et al.*, 2006). On the other hand, the number of plications performed, plaque size, and hinge/narrowing effect due to a PD plaque did not have a significant impact on penile length loss.

In a report of 89 PD patients treated with a Nesbitt plication since 1990, 91% reported complete correction of curvature and 89% had preserved erectile function (Cantoro *et al.*, 2014). Similarly, in 106 PD patients treated with the Yachia technique, 95% reported straightening that allowed for successful intercourse (Lopes *et al.*, 2013). Overall, the literature suggests that, regardless of plication technique, one can expect full straightening in

85–100% of patients, new ED in 0–13%, and patient satisfaction in 70–100% (Levine & Burnett, 2013).

Tunica albuginea plication is an attractive option to surgeons because it is a simple, minimally invasive procedure that generally preserves potency. It, unfortunately, almost invariably results in loss of penile length and does not correct a hinge or hourglass defect and may actually aggravate it, leading to an unstable penis. Furthermore, it can be associated with decreased sensation and complaints of superficial suture knot irritation.

Tunical lengthening procedures

Commonly used tunical lengthening procedures include partial excision or incision and grafting (PEG). Incision and partial plaque excision have largely displaced the previously widely used complete plaque excision because of the significant increase in ED associated with the latter (Gelbard, 1995; Ralph *et al.*, 2010). As a matter of fact, even with incision and partial excision, post-operative diminishing erectile function can be anticipated and patients should be counseled accordingly (Taylor *et al.*, 2012). As such, the main indications for PEG include a patient with more severe deformity (curvature $>60^{\circ}$ – 70° , hinging, severe plaque calcification) with adequate erections, and who acknowledge the potential for worsening erectile function post-operatively (Flores *et al.*, 2011; Taylor *et al.*, 2012).

An incision can be performed using the traditional modified H or double Y-incision in the area of maximum curvature (Gelbard, 1995). This allows for tunic expansion and, ultimately, curvature correction. On occasion, multiple incisions and, sometimes, additional tunical plication, may be needed to attain satisfactory straightening (Levine & Burnett, 2013). More recently, newer techniques have been described using geometrical principles aimed at obtaining more accurate graft sizes (Egydio *et al.*, 2004; Miranda & Sampaio, 2014). Furthermore, when the plaque is very dense and causes severe indentation, it is sometimes advisable to proceed with a partial excision of the plaque to allow for better correction of the narrowing (Sherer *et al.*, 2014).

The perfect graft material is yet to be found. Historically, a wide variety of graft materials have been used and include autologous grafts such as dermis, saphenous vein, buccal mucosa, proximal crura, tunica vaginalis, dura mater, temporalis fascia and fascia lata; and synthetic grafts such as Dacron and polytetrafluoroethylene (PTFE). (Kadioglu *et al.*, 2007; Levine & Burnett, 2013). Drawbacks of patient-harvested grafts include increased length of surgery and associated harvest-site morbidity, while drawbacks of Dacron and PTFE include increased risks of inflammation, fibrosis, and infection (Brannigan *et al.*, 1998). More recently, xenografts and allografts such as Tutoplast processed human and bovine pericardium (Coloplast US, Minneapolis, MN, USA) and small intestinal submucosa (SIS) grafts (Surgisis ES; Cook Urological, Spencer, IN, USA) have emerged as attractive options for urologists. Our preference is for processed human pericardium, as it is thin, strong, with rare reported infections and contracts less than SIS (up to 25%) (Hellstrom & Reddy, 2000; Chung *et al.*, 2011). Table 3 summarizes grafts used in the surgical treatment of PD.

Overall, in well-selected patients, PEG may help achieve adequate penile straightening in 80–100% of patients with satisfaction rates as high as 70–100% (Hatzimouratidis *et al.*, 2012). Following surgery, complication rates as high as 16% penile hypoaesthesia, 16% persistent/recurrent curvature, and 15% ED can

Table 3 Grafts used in the surgical treatment of Peyronie's disease

Autologous grafts
Dermis
Vein grafts
Tunica albuginea
Tunica vaginalis
Temporalis fascia
Buccal mucosa
Allografts
Cadaveric pericardium
Cadaveric fascia lata
Cadaveric dura matter
Cadaveric dermis
Xenografts
Porcine small intestinal submucosa
Bovine pericardium
Porcine dermis
Synthetic grafts
Gore-Tex
Dacron

be expected (Hatzimouratidis *et al.*, 2012). Naturally, the larger the size of the defect at the time of PEG (≥ 3 cm), the higher the rate of post-operative ED (Kozacioglu *et al.*, 2012).

Penile prosthesis implantation

In a study evaluating factors predictive of ED following surgical correction of PD without inflatable penile prosthesis (IPP) placement, the direction of curvature, surgical approach, graft area, and medical history was not predictive of having post-operative ED. Only preoperative ED was found to be predictive in this series (Taylor *et al.*, 2012). Based on this knowledge, current guidelines recommend insertion of a PP in men with poor erections and/or those with inadequate response to pharmacological ED therapy (Yafi *et al.*, 2015). In patients with PD and concomitant ED, insertion of a PP helps address both the functionality and configuration of the penis.

While both a malleable prosthesis and IPP may be used in patients with ED without PD, comparative data strongly suggest higher rates of patient dissatisfaction, residual curvature, and unsuccessful straightening with a malleable prosthesis in patients with both PD and ED and, as such, IPP insertion is preferred in this setting (Montorsi *et al.*, 1993; Ghanem *et al.*, 1998). Furthermore, if an IPP is being considered for the treatment of PD, the literature reports no difference in outcomes between the two most commonly used types of IPP: the AMS 700 CX (American Medical Systems, Minneapolis, MN, USA) and the Titan (Coloplast) (Chung *et al.*, 2012). When used in combination with penile modeling, both devices achieve patient satisfaction rates as high as 86–90% (Chung *et al.*, 2012).

In patients with minimal curvature or an unstable penis secondary to indentation or hourglass deformity, insertion of an IPP alone may often be sufficient (Levine & Burnett, 2013). As a matter of fact, the need for ancillary straightening procedures correlates directly with the degree of penile angulation (no maneuvers needed for curvatures $\leq 30^{\circ}$ vs. 100% for curvatures $>60^{\circ}$) (Mulhall *et al.*, 2004). If adequate straightening is not attained with IPP insertion alone, the first step in the straightening algorithm, penile manual modeling, is attempted. This is performed by inserting, then inflating, the IPP cylinders, followed by bending the penis in the contralateral direction to the

curvature for two cycles of 90 sec each (Wilson & Delk, 1994). The major risk associated with this technique is distal urethral injury in 3% of patients (Wilson *et al.*, 2001). This can, however, be avoided with judicious placement of hands on the shaft, base of penis, and forward pressure on the open corporotomies during modeling (Yafi *et al.*, 2015). An alternative involves plication prior to IPP insertion; however, this may be associated with additional loss of length (Chung *et al.*, 2014).

If satisfactory penile straightening is not achieved (>30° after 2 rounds of manual modeling), or there is residual indentation causing the inflated cylinder to buckle, the next steps may include plication, multiple tunical incisions or, occasionally, excision with or without grafting (Yafi *et al.*, 2015; Levine & Burnett, 2013; Zaid *et al.*, 2014). When the tunical defect is larger than 2 cm, the general consensus is to proceed with grafting (Carson & Levine, 2014). If a graft is used in this setting, autologous dermal grafts should be avoided to minimize contraction and the theoretical risks of bacterial seeding and subsequent prosthesis infection (Ralph *et al.*, 2010).

One of the most common complaints following insertion of an IPP is penile shortening in up to 50% of patients (Wang *et al.*, 2009). Recently, various methods to circumvent loss of penile length have been described and include the use of complex geometrical measurements, various flaps, the 'sliding technique', transcorporeal incisions, and relaxing incisions with vein grafts concurrently with an IPP (Egydio & Sansalone, 2008; Egydio *et al.*, 2013; Rolle *et al.*, 2012; Sansalone *et al.*, 2012; Shaeer, 2010, 2011; Silvani *et al.*, 2012). Alternatively, less invasive options, such as penile massage with cocoa butter, penile stretching exercises with traction devices, and nightly use of phosphodiesterase inhibitors, have been reported with mixed results (Yafi *et al.*, 2015). Other recognizable complications of IPP insertion include hypoesthesia and paresthesia, difficulties using and deflating the device, mechanical failure, erosion, and infections (Zaid *et al.*, 2014).

CONCLUSIONS

Peyronie's disease continues to be under diagnosed and its pathophysiology has not been completely elucidated. There are currently a myriad of oral medications available for the management of the acute phase of PD, but the scientific evidence for their use is weak. Intralesional CCH is the only currently FDA-approved drug for the management of PD. Its indications are, however, limited to patients with palpable plaque with dorsal or dorsolateral curvature >30°. Alternative ILI options include verapamil and interferon alpha-2B, but their use is considered off-label. Traction therapy, as part of a multimodal approach, is an underused additional tool for the prevention of PD-associated loss of penile length, but its efficacy is dependent on patient compliance. Surgical therapy remains the standard of care for patients in the chronic phase of the disease. In patients with adequate erectile function, tunical plication and/or incision/partial excision and grafting can be offered. In patients with ED non-responsive to oral therapy, insertion of an IPP with or without straightening procedures needs to be offered.

ACKNOWLEDGMENTS

None.

AUTHOR CONTRIBUTIONS

FAY drafted manuscript, collected data, and revised manuscript; MP drafted manuscript; PS drafted manuscript; WJGH reviewed and revised manuscript, supervised.

REFERENCES

- Abern M & Levine L. (2008) Intralesional injections with and without penile traction and oral therapies for management of Peyronie's disease. *J Urol* 179, 408.
- Abern MR, Larsen S & Levine LA. (2012) Combination of penile traction, intralesional verapamil, and oral therapies for Peyronie's disease. *J Sex Med* 9, 288–95.
- Andrews HO, al-Akraa M, Pryor JP & Ralph DJ. (1999) The Nesbit operation for congenital curvature of the penis. *Int J Impot Res* 11:119–22.
- Baskin LS & Duckett JW. (1994) Dorsal tunica albuginea plication for hypospadias curvature. *J Urol* 151, 1668–71.
- Bennett NE, Guhring P & Mulhall JP. (2007) Intralesional verapamil prevents the progression of Peyronie's disease. *Urology* 69, 1181–4.
- Biagiotti G & Cavallini G. (2001) Acetyl-L-carnitine vs tamoxifen in the oral therapy of Peyronie's disease: a preliminary report. *BJU Int* 88, 63–67.
- Bjekic MD, Vlajinac HD, Sipetic SB & Marinkovic JM. (2006) Risk factors for Peyronie's disease: a case-control study. *BJU Int* 97(3), 570–4.
- Brannigan RE, Kim ED, Oyasu R & McVary KT. (1998) Comparison of tunica albuginea substitutes for the treatment of Peyronie's disease. *J Urol* 159, 1064–8.
- Brant WO, Bella AJ & Lue TF. (2007) 16-dot procedure for penile curvature. *J Sex Med* 2, 277–80.
- Cantoro U, Polito M, Catanzariti F, Montesi L, Lacetera V & Muzzonigro G. (2014) Penile plication for Peyronie's disease: our results with mean follow-up of 103 months on 89 patients. *Int J Impot Res* 26, 156–9.
- Carson CC & Levine LA. (2014) Outcomes of surgical treatment of Peyronie's disease. *BJU Int* 113, 704–13.
- Castiglione F, Hedlund P, Vanderaa F, Bivalacqua TJ, Rigatti P, Van Poppel H, Montorsi F, De Ridder D & Albersen M. (2013) Intratunical injection of human adipose tissue-derived stem cells prevents fibrosis and is associated with improved erectile function in a rat model of Peyronie's disease. *Eur Urol* 63, 551–60.
- Cavallini G, Modenini F & Vitali G. (2007) Open preliminary randomized prospective clinical trial of efficacy and safety of three different verapamil dilutions for intraplaque therapy of Peyronie's disease. *Urology* 69, 950–4.
- Chung E, Deyoung L & Brock GB. (2011) The role of PDE5 inhibitors in penile septal scar remodeling: assessment of clinical and radiological outcomes. *J Sex Med* 8, 1472–1477.
- Chung E, Solomon M, Deyoung L & Brock GB. (2012) Comparison between AMS 700TM CX and ColoplastTM Titan inflatable penile prosthesis for Peyronie's disease treatment and remodeling: clinical outcomes and patient satisfaction. *J Sex Med* 10, 2855–60.
- Chung PH, Scott JF & Morey AF. (2014) High patient satisfaction of inflatable penile prosthesis insertion with synchronous penile plication for erectile dysfunction and Peyronie's disease. *J Sex Med* 11, 1593–8.
- Cortes-Gonzalez JR & Glina S. (2010) Conservative treatment of Peyronie's disease: colchicine vs. colchicine plus vitamin E. *Actas Urol Esp* 34, 444–449.
- Desai CK, Huang J, Lokhandwala A, Fernandez A, Riaz IB & Alpert JS. (2014) The role of vitamin supplementation in the prevention of cardiovascular disease events. *Clin Cardiol* 37, 576–81.
- DiStasi SM, Giannantoni A, Stephen RL, Capelli G, Giurioli A, Jannini EA & Vespasiani G. (2004) A prospective, randomized study using transdermal electromotive administration of verapamil and dexamethasone for Peyronie's disease. *J Urol* 171, 1605–8.
- Domes T, De Young L, O'Gorman DB, Gan BS, Bella AJ & Brock G. (2007) Is there a role for proteomics in Peyronie's disease? *J Sex Med* 4, 867–77.

- Duncan MR, Berman B & Nseyo UO. (1991) Regulation of the proliferation and biosynthetic activities of cultured human Peyronie's disease fibroblasts by interferons-alpha, -beta and -gamma. *Scand J Urol Nephrol* 25, 89–94.
- Egydio PH & Sansalone S. (2008) Peyronie's reconstruction for maximum length and girth gain: geometrical principles. *Adv Urol*. Epub Dec 3, 05739.
- Egydio PH, Lucon AM & Arap S. (2004) A single relaxing incision to correct different types of penile curvature: surgical technique based on geometrical principles. *BJU Int* 94, 1147–57.
- Egydio PH, Kuehhas FE & Sansalone S. (2013) Penile length and girth restoration in severe Peyronie's disease using circular and longitudinal grafting. *BJU Int* 111, E213–9.
- El-Sakka AI, Bakircioglu ME, Bhatnagar RS, Yen TS, Dahiya R & Lue TF. (1999) The effects of colchicine on a Peyronie's-like condition in an animal model. *J Urol* 161, 1980–1983.
- Essed E & Schroeder FH. (1985) New surgical treatment for Peyronie's disease. *Urology* 25, 582–587.
- Favilla V, Russo GI, Privitera S, Castelli T, Madonia M, La Vignera S, Condorelli R, Calogero AE, Farina FP, Cimino S & Morgia G. (2014) Combination of intralesional verapamil and oral antioxidants for Peyronie's disease: a prospective, randomised controlled study. *Andrologia* 46, 936–42.
- Flores S, Choi J, Alex B & Mulhall JP. (2011) Erectile dysfunction after plaque incision and grafting: short-term assessment of incidence and predictors. *J Sex Med* 8, 2031–7.
- Gelbard MK. (1995) Relaxing incisions in the correction of penile deformity due to Peyronie's disease. *J Urol* 154, 1457–60.
- Gelbard MK, Walsh R & Kaufman JJ. (1982) Collagenase for Peyronie's disease experimental studies. *Urol Res* 10, 135–40.
- Gelbard MK, Lindner A & Kaufman JJ. (1985) The use of collagenase in the treatment of Peyronie's disease. *J Urol* 134, 280–3.
- Gelbard MK, Dorey F & James K. (1990) The natural history of Peyronie's disease. *J Urol* 144, 1376–9.
- Gelbard M, Goldstein I, Hellstrom WJ, McMahon CG, Smith T, Tursi J, Jones N, Kaufman G & Carson CC 3rd. (2013a) Clinical efficacy, safety and tolerability of collagenase clostridium histolyticum for the treatment of Peyronie's disease in 2 large double-blind, randomized, placebo controlled phase 3 studies. *J Urol* 190, 199–207.
- Gelbard M, Hellstrom WJ, McMahon CG, Levine LA, Smith T, Tursi J, Kaufman G & Goldstein I. (2013b) Baseline characteristics from an ongoing phase 3 study of collagenase clostridium histolyticum in patients with Peyronie's disease. *J Sex Med* 10, 2822–31.
- Ghanem HM, Fahmy I & el-Meliigy A. (1998) Malleable penile implants without plaque surgery in the treatment of Peyronie's disease. *Int J Impot Res*. 10:171–3.
- Gholami SS & Lue TF. (2002) Correction of penile curvature using the 16-dot plication technique: a review of 132 patients. *J Urol* 167, 2066–9.
- Gokce A, Abd Elmageed ZY, Lasker GF, Bouljihad M, Kim H, Trost LW, Kadowitz PJ, Abdel-Mageed AB, Sikka SC & Hellstrom WJ. (2014) Adipose tissue-derived stem cell therapy for prevention and treatment of erectile dysfunction in a rat model of Peyronie's disease. *Andrology* 2, 244–51.
- Gontero P, Di Marco M, Guibilei G, Bartoletti R, Pappagallo G, Tizzani A & Mondaini N. (2009) Use of penile extender device in the treatment of penile curvature as a result of Peyronie's disease. Results of a phase II prospective study. *J Sex Med* 6, 558–66.
- Gonzalez-Cadavid NF & Rajfer J. (2010) Treatment of Peyronie's disease with PDE5 inhibitors: an antifibrotic strategy. *Nat Rev Urol* 7, 215–221.
- Greenfield JM, Lucas S & Levine LA. (2006) Factors affecting the loss of length associated with tunical albuginea plication for correction of penile curvature. *J Urol* 175, 238–41.
- Greenfield JM, Shah SJ & Levine LA. (2007) Verapamil versus saline in electromotive drug administration for Peyronie's disease: a double-blind, placebo-controlled trial. *J Urol* 177, 972–5.
- Gur S, Limin M & Hellstrom WJ. (2011) Current status and new developments in Peyronie's disease: medical, minimally invasive and surgical treatment options. *Expert Opin Pharmacother* 12, 931–944.
- Haag SM, Hauck EW, Szardening-Kirchner C, Diemer T, Cha ES, Weidner W & Eickelberg O. (2007) Alterations in the transforming growth factor (TGF)-beta pathway as a potential factor in the pathogenesis of Peyronie's disease. *Eur Urol* 51, 255–61.
- Hashimoto K, Hisasue S, Kato R, Kobayashi K, Shimizu T & Tsukamoto T. (2006) Outcome analysis for conservative management of Peyronie's disease. *Int J Urol* 13, 244–247.
- Hatzichristodoulou G, Meisner C, Gschwend JE, Stenzl A & Lahme S. (2013) Extracorporeal shock wave therapy in Peyronie's disease: results of a placebo-controlled, prospective, randomized single-blind study. *J Sex Med* 10, 2815–21.
- Hatzimouratidis K, Eardley I, Giuliano F, Hatzichristou D, Moncada I, Salonia A, Vardi Y & Wespes E; European Association of Urology. (2012) EAU guidelines on penile curvature. *Eur Urol* 62, 543–52.
- Hauck EW, Mueller UO, Bschiepfer T, Schmelz HU, Diemer T & Weidner W. (2004) Extracorporeal shock wave therapy for Peyronie's disease: exploratory meta-analysis of clinical trials. *J Urol* 171, 740–5.
- Hellstrom WJ & Reddy S. (2000) Application of pericardial graft in the surgical management of Peyronie's disease. *J Urol* 163, 1445–7.
- Hellstrom WJ, Kendirci M, Matern R, Cockerham Y, Myers L, Sikka SC, Venable D, Honig S, McCullough A, Hakim LS, Nehra A, Templeton LE & Pryor JL. (2006) Single-blind, multicenter, placebo controlled, parallel study to assess the safety and efficacy of intralesional interferon alpha-2B for minimally invasive treatment for Peyronie's disease. *J Urol* 176, 394–8.
- Hellstrom WJ, Feldman R, Rosen RC, Smith T, Kaufman G & Tursi J. (2013) Bother and distress associated with Peyronie's disease: validation of the Peyronie's disease questionnaire. *J Urol* 190, 627–34.
- Inal T, Tokatli Z, Akand M, Ozdiler E & Yaman O. (2006) Effect of intralesional interferon-alpha 2b combined with oral vitamin E for treatment of early stage Peyronie's disease: a randomized and prospective study. *Urology* 67, 1038–1042.
- Incrocci L, Wijnmaalen A, Slob AK, Hop WC & Levendag PC. (2000) Low-dose radiotherapy in 179 patients with Peyronie's disease: treatment outcome and current sexual functioning. *Int J Radiat Oncol Biol Phys* 47, 1353–6.
- Kadioglu A, Tefekli A, Koksalt U, Usta M & Erol H. (2000) Treatment of Peyronie's disease with oral colchicine: long-term results and predictive parameters of successful outcome. *Int J Impot Res* 12, 169–75.
- Kadioglu A, Sanli O, Akman T, Ersay A, Guven S & Mammadov F. (2007) Graft materials in Peyronie's disease surgery: a comprehensive review. *J Sex Med* 4, 581–95.
- Kendirci M, Usta MF, Matern RV, Nowfar S, Sikka SC & Hellstrom WJ. (2005) The impact of intralesional interferon alpha-2b injection therapy on penile hemodynamics in men with Peyronie's disease. *J Sex Med Sep* 2(5), 709–15.
- Klein EA, Thompson IM Jr, Tangen CM, Crowley JJ, Lucia MS, Goodman PJ, et al. (2011) Vitamin E and the risk of prostate cancer: the Selenium and Vitamin E Cancer Prevention Trial (SELECT). *JAMA* 306, 1549–1556.
- Kozacioglu Z, Degirmenci T, Gunlusoy B, Kara C, Arslan M, Ceylan Y & Minareci S. (2012) Effect of tunical defect size after Peyronie's plaque excision on postoperative erectile function: do centimeters matter? *Urology* 80, 1051–5.
- Levine LA & Burnett AL. (2013) Standard operating procedures for Peyronie's disease. *J Sex Med* 10, 230–44.

- Levine L & Rybak J. (2011) Traction therapy for men with shortened penis prior to penile prosthesis implantation: a pilot study. *J Sex Med* 8, 2112–7.
- Levine LA, Merrick PF & Lee RC. (1994) Intralesional verapamil injection for the treatment of Peyronie's disease. *J Urol* 151, 1522–4.
- Levine LA, Goldman K & Greenfield J. (2002) Experience with intraplaque injection of verapamil for Peyronie's disease. *J Urol* 168, 36.
- Levine L, Newell M & Taylor F. (2008) Penile traction therapy for treatment of Peyronie's disease: a single-center pilot study. *J Sex Med* 5, 1468–73.
- Lin CS & Lue TF. (2013) Adipose-derived stem cells for the treatment of Peyronie's disease? *Eur Urol* 63, 561–2.
- Lopes I, Tomada N & Vendeira P. (2013) Penile corporoplasty with Yachia's technique for Peyronie's disease: single center experience with 117 patients. *Urol Ann* 5, 167–71.
- Martin DJ, Badwan K, Parker M & Mulhall JP. (2002) Transdermal application of verapamil gel to the penile shaft fails to infiltrate the tunica albuginea. *J Urol* 168, 2483–5.
- Martinez-Salamanca JI, Equi A, Moncada I, Minaya J, Ballesteros CM, Del Portillo L, Sola I & Carballido J. (2014) Acute phase Peyronie's disease management with traction device: a nonrandomized prospective controlled trial with ultrasound correlation. *J Sex Med* 11, 506–15.
- Miranda AF & Sampaio FJ. (2014) A Geometric model of plaque incision and graft for Peyronie's disease with geometric analyses of different techniques. *J Sex Med* 11, 1546–53.
- Moncada-Iribarren I, Jara J, Martinex-Salamanca J, et al. (2007) Managing penile shortening after Peyronie's disease surgery. *J Urol* 177(Suppl. 4), 252.
- Montorsi F, Guazzoni G, Bergamaschi F & Rigatti P. (1993) Patient-partner satisfaction with semirigid penile prostheses for Peyronie's disease: a 5-year follow-up study. *J Urol* 150, 1819–21.
- Mulhall J, Ahmed A & Anderson M. (2004) Penile prosthetic surgery for Peyronie's disease: defining the need for intraoperative adjuvant maneuvers. *J Sex Med* 1, 318–21.
- Mulhall JP, Schiff J & Guhring P. (2006) An analysis of the natural history of Peyronie's disease, discussion 2118. *J Urol*, 175: 2115–8.
- Mulhall JP, Hall M, Broderick GA & Incrocci L. (2012) Radiation therapy in Peyronie's disease. *J Sex Med* 9, 1435–41.
- Nesbit RM. (1954) The surgical treatment of congenital chordee without hypospadias. *J Urol* 72, 1178–1180.
- Ozturk U, Yesil S, Goktug HN, Gucuk A, Tuygun C, Sener NC, Nalbant I & Imamoglu MA. (2014) Effects of sildenafil treatment on patients with Peyronie's disease and erectile dysfunction. *Ir J Med Sci* 183, 449–453.
- Palmieri A, Imbimbo C, Longo N, Fusco F, Verze P, Mangiapia F, Creta M & Mirone V. (2009) A first prospective, randomized, double-blind, placebo-controlled clinical trial evaluating extracorporeal shock wave therapy for the treatment of Peyronie's disease. *Eur Urol* 56, 363–9.
- Paulis G & Brancato T. (2012) Inflammatory mechanisms and oxidative stress in Peyronie's disease: therapeutic "rationale" and related emerging treatment strategies. *Inflamm Allergy Drug Targets* 11, 48–57.
- Paulis G, Brancato T, D'Ascenzo R, De Giorgio G, Nupieri P, Orsolini G & Alvaro R. (2013) Efficacy of vitamin E in the conservative treatment of Peyronie's disease: legend or reality? A controlled study of 70 cases. *Andrology* 1, 120–128.
- Peters H, Border WA & Noble NA. (2000) Tandem antifibrotic actions of L-arginine supplementation and low protein diet during the repair phase of experimental glomerulonephritis. *Kidney Int* 57, 992–1001.
- Piao S, Ryu JK, Shin HY, Zhang L, Song SU, Han JY, Park SH, Kim JM, Kim IH, Kim SJ & Suh JK. (2008) Repeated intratunical injection of adenovirus expressing transforming growth factor-beta1 in a rat induces penile curvature with tunical fibrotic plaque: a useful model for the study of Peyronie's disease. *Int J Androl* 31, 346–53.
- Prieto Castro RM, Leva Vallejo ME, Regueiro Lopez JC, Anglada Curado FJ, Alvarez Kindelan J & Requena Tapia MJ. (2003) Combined treatment with vitamin E and colchicine in the early stages of Peyronie's disease. *BJU Int* 91, 522–524.
- Pryor JP & Farell CF. (1983) Controlled clinical trial of vitamin E in Peyronie's disease. *Prog Reprod Biol* 9, 41–45.
- Qian A, Meals RA, Rajfer J & Gonzalez-Cadavid NF. (2004) Comparison of gene expression profiles between Peyronie's disease and Dupuytren's contracture. *Urology* 64, 399–404.
- Raetsch C, Jia JD, Boigk G, Bauer M, Hahn EG, Riecken EO & Schuppan D. (2002) Pentoxifylline downregulates profibrogenic cytokines and procollagen I expression in rat secondary biliary fibrosis. *Gut* 50, 241–247.
- Ralph DJ, Brooks MD, Bottazzo GF & Pryor JP. (1992) The treatment of Peyronie's disease with tamoxifen. *Br J Urol* 70, 648–651.
- Ralph D, Gonzalez-Cadavid N, Mirone V, Perovic S, Sohn M, Usta M & Levine L. (2010) The medical management of Peyronie's disease: evidence-based 2010 guidelines. *J Sex Med* 7, 2359–74.
- Rehman J, Benet A & Melman A. (1998) Use of intralesional verapamil to dissolve Peyronie's disease plaque: a long-term single blind study. *Urology* 51, 620–6.
- Riedl CR, Plas E, Engelhardt P, Daha K & Pflüger H. (2000) Iontophoresis for treatment of Peyronie's disease. *J Urol* 163, 95–9.
- Rochelle JC & Levine LA. (2005) Survey of primary care physicians and urologist regarding peyronie's disease. *J Urol* 173(Suppl), 254.
- Rolle L, Ceruti C, Timpano M, Sedigh O, Destefanis P, Galletto E, Falcone M & Fontana D. (2012) A new, innovative lengthening surgical procedure for Peyronie's disease by penile prosthesis implantation with double dorsal-ventral patch graft: the "sliding technique". *J Sex Med* 9, 2389–95.
- Safarinejad MR. (2004) Therapeutic effects of colchicine in the management of Peyronie's disease: a randomized double-blind, placebo-controlled study. *Int J Impot Res* 16, 238–243.
- Safarinejad MR, Hosseini SY & Kolahi AA. (2007). Comparison of vitamin E and propionyl-L-carnitine, separately or in combination, in patients with early chronic Peyronie's disease: a double-blind, placebo controlled, randomized study, discussion 1403. *J Urol* 178, 1398–1403.
- Safarinejad MR, Asgari MA, Hosseini SY & Dadkhah F. (2010) A double-blind placebo-controlled study of the efficacy and safety of pentoxifylline in early chronic Peyronie's disease. *BJU Int* 106, 240–248.
- Sansalone S, Garaffa G, Djinovic R, Egydio P, Vespasiani G, Miano R, Loreto C & Ralph DJ. (2012) Simultaneous penile lengthening and penile prosthesis implantation in patients with Peyronie's disease, refractory erectile dysfunction, and severe penile shortening. *J Sex Med* 9, 316–21.
- Schandene L, Vandenbussche P, Crusiaux A, Alegre ML, Abramowicz D, Dupont E, Content J & Goldman M. (1992) Differential effects of pentoxifylline on the production of tumour necrosis factor-alpha (TNF-alpha) and interleukin-6 (IL-6) by monocytes and T cells. *Immunology* 76, 30–34.
- Scott WW & Scardino PL. (1948) A new concept in the treatment of Peyronie's disease. *South Med J* 41, 173–177.
- Shaeer O. (2010) Supersizing the penis following penile prosthesis implantation. *J Sex Med* 7, 2608–16.
- Shaeer O. (2011) Trans-corporal incision of Peyronie's plaques. *J Sex Med* 8, 589–93.
- Sherer BA, Warrior K & Levine LA. (2014) 2013–2014 updates in Peyronie's disease management. *Curr Urol Rep* 15, 459.
- Shindel AW, Lin G, Ning H, Banie L, Huang YC, Liu G, Lin CS & Lue TF. (2010) Pentoxifylline attenuates transforming growth factor-beta1-stimulated collagen deposition and elastogenesis in human tunica albuginea-derived fibroblasts part 1: impact on extracellular matrix. *J Sex Med* 7, 2077–2085.
- Shirazi M, Haghpanah AR, Badiie M, Afrasiabi MA & Haghpanah S. (2009) Effect of intralesional verapamil for treatment of Peyronie's disease: a randomized single-blind, placebo controlled study. *Int Urol Nephrol* 41, 467–71.

- Silvani M, Pecoraro S & Zucchi A. (2012) Corporoplasty for induratio penis plastica with soft axial tutors, single relaxing albugineal incision and safenous grafting. A 3-year follow up. *Arch Ital Urol Androl* 84, 84–8.
- Soh J, Kawauchi A, Kanemitsu N, Naya Y, Ochiai A, Naitoh Y, Fujiwara T, Kamoi K & Miki T. (2010) Nicardipine vs. saline injection as treatment for Peyronie's disease: a prospective, randomized, single-blind trial. *J Sex Med* 7, 3743–9.
- Stoesesandt J, Kurzinger N, Brocker EB & Trautmann A. (2010) Urodermatological problems of a construction worker: paraaminobenzoic acid as a systemic photosensitizer. *Eur J Dermatol* 20, 217–219.
- Taylor F, Abern M & Levine LA. (2012) Predicting erectile dysfunction following surgical correction of Peyronie's disease without inflatable penile prosthesis placement: vascular assessment and preoperative risk factors. *J Sex Med* 9, 296–301.
- Teasley GH. (1954) Peyronie's disease; a new approach. *J Urol* 71, 611–4.
- Teloken C, Rhoden EL, Grazziotin TM, Ros CT, Sogari PR & Souto CA. (1999) Tamoxifen versus placebo in the treatment of Peyronie's disease. *J Urol* 162, 2003–2005.
- Trost LW, Ates E, Powers M, Sikka S & Hellstrom WJ. (2013) Outcomes of intralesional interferon- α 2B for the treatment of Peyronie disease. *J Urol* 190, 2194–9.
- Usta MF, Bivalacqua TJ, Tokatli Z, Rivera F, Gulkesen KH, Sikka SC & Hellstrom W. (2004) Stratification of penile vascular pathologies in patients with Peyronie's disease and in men with erectile dysfunction according to age: a comparative study. *J Urol* 172, 259–62.
- Valente EG, Vernet D, Ferrini MG, Qian A, Rajfer J & Gonzalez-Cadavid NF. (2003) L-arginine and phosphodiesterase (PDE) inhibitors counteract fibrosis in the Peyronie's fibrotic plaque and related fibroblast cultures. *Nitric Oxide* 9, 229–244.
- Wang R, Howard GE, Hoang A, Yuan JH, Lin HC & Dai YT. (2009) Prospective and long-term evaluation of erect penile length obtained with inflatable penile prosthesis to that induced by intracavernosal injection. *Asian J Androl* 11, 411–5.
- Weidner W, Hauck EW & Schnitker J; Peyronie's Disease Study Group of Andrological Group of German U. (2005). Potassium paraaminobenzoate (POTABA) in the treatment of Peyronie's disease: a prospective, placebo-controlled, randomized study, discussion 535–536. *Eur Urol* 47, 530–535.
- Williams JL & Thomas GG. (1970) The natural history of Peyronie's disease. *J Urol* 103, 75–6.
- Wilson SK & Delk JR 2nd. (1994) A new treatment for Peyronie's disease: modeling the penis over an inflatable penile prosthesis. *J Urol* 152, 1121–3.
- Wilson SK, Cleves MA & Delk JR. (2001) Long-term follow-up of treatment for Peyronie's disease: modeling the penis over an inflatable penile prosthesis. *J Urol* 165, 825–9.
- Yachia D. (1990) Modified Corporoplasty for the treatment of penile curvature. *J Urol* 143, 80–2.
- Yafi FA, Pinsky MR, Stewart C, Premsant S, Ates E, Trost LW, Suresh SC & Hellstrom WJ. (2014) The effect of duration of penile traction therapy in patients undergoing intralesional injection therapy for peyronie's disease. *J Urol* Mar 21.pii: S0022-5347(15)03393-5. doi: 10.1016/j.juro.2015.03.092.
- Yafi FA, Sangkum P, McCaslin IR & Hellstrom WJ. (2015) Strategies for penile prosthesis placement in Peyronie's disease and corporal fibrosis. *Curr Urol Rep* 16, 491.
- Zaid UB, Alwaal A, Zhang X, Lue TF. (2014) Surgical management of Peyronie's disease. *Curr Urol Rep*. Oct; 15(10):446. doi: 10.1007/s11934-014-0446-x.
- Zarafonitis CJ. (1953) Clinical use of paraaminobenzoic acid. *Tex State J Med* 49, 666–672.
- Zarafonitis CJ & Horrax TM. (1959) Treatment of Peyronie's disease with potassium para-aminobenzoate (potaba). *J Urol* 81, 770–772.